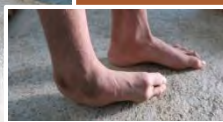



患先天性馬蹄肉翻
的兩姊妹
Siblings with
congenital clubfoot



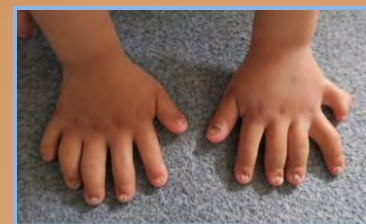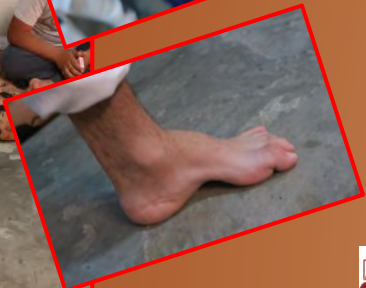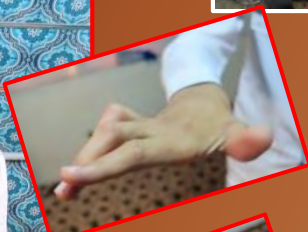患腦癱的男孩
A boy with
cerebral palsy



患遺神經病者手和腳都有變型
Patient with hereditary neuropathy
showing deformity in hands and feet

www.his-foundation.org HISFound@aol.com

患不同骨科病的難民
Refugees with
different orthopedic
conditions



患膝外翻及多指的女童
Girl with knock knees
and polydactyly

伊拉克難民營 Refugee Camp in Iraq

1



2



5



3



1,2,3,4 聯合國難民營 U.N. refugee camp
5 天鄰義工到難民營甄選病人 HIS volunteer screen patients in refuge camp
6 聯合國難民營已滿, 未能住進難民營的孩子 UN camps are full. Children unable to get admitted to refugee camp
7 這個難民家庭住在棄置的房屋 This refugee family lives in a house that is abandoned

4

